Veterinary Care & Specialty Group

VCSG

3201 Broad Street
Chattanooga, TN 37408
info@vcsgvets.com
www.vcsgvets.com

423-591-0270

24/7/365

July 2021

In this edition.....

Connect with us on social media!

@VCSGvets

@vcsgvets

VCSG Fifth Annual Continuing Education Conference

August 21, 2021

Details and registration information coming soon.

RACE APPROVED!

WELCOME TO DR. WILL UNDERWOOD

As a nontraditional veterinarian, Dr. Underwood left his freelance photography and graphic design business to pursue a career in veterinary medicine. In 2018 he graduated from the University of Tennessee College of Veterinary Medicine. After graduation he joined the United States Army Veterinary Corps where he served from 2018 - 2021 as the Officer in Charge (OIC) of the Ft. Carson Veterinary Treatment Center. During that time, he cared for privately owned animals and government owned animals, including Military Working Dogs, Military Working Equines, and even the United States Air Force Academy's mascot falcons. In 2022, he will be transferred to the Individual Ready Reserve (IRR).

Dr. Underwood has a passion for surgery and exotics and has previously spent time caring for exotic birds, reptiles, and ring-tailed lemurs. During his free time, Dr. Underwood enjoys kickboxing and Brazilian Jiu-Jitsu, going to breweries with friends, and hiking with his American Bulldog, Judah.



Dr. Will Underwood

Vader's Friends of the Month

Vader Pullen

Ask the Vet

Splenectomy in Dogs and Cats

Ray Rudd,
DVS, MS, DACVS

Dr. Rudd is a Surgeon at VCSG.

The spleen is considered a part of the reticuloendothelial system and can contribute to hematopoiesis in some cases. The blood supply to the spleen is through the splenic artery and short gastric arteries. In the dog, contraction can be responsible for changes in the packed cell volume of 10-20%. The spleen acts as a filter to remove old red blood cells in both the dog and cat by use of a narrow opening in which they must pass. In dogs, this opening is narrower and Howell-Jolly bodies and Heinz bodies are removed here; in cats this opening is wider and is a presumptive reason for the presence of Howell-Jolly bodies seen more frequently in cats. There is a role for B and T cell presence and antibody production. Nevertheless, dogs and cats can function normally without a spleen since the liver will assume its functions.

Splenectomies are done routinely at VCSG in both dogs and cats. Historically, a ruptured spleen due to motor vehicle trauma has not been uncommon, although fewer cases now are likely the result of better management of keeping pets from the roadways. Splenomegaly can be symmetrical or non-symmetrical. Occasionally the splenic enlargement is palpable on physical examination. Symmetrical enlargement may be normal in some cases, but extremely large spleens are not normal. There are occasionally nodules present on the spleen that may be normal. Nodules on the spleen should not be considered benign since approximately two thirds are malignant with the majority of these being a hemangiosarcoma. In addition, about 70% that have internal bleeding due to a ruptured spleen have hemangiosarcoma. There is a condition of nodular hyperplasia that consists of lymphoid hyperplasia.

(Continued on next page)

(Continued from previous page)

Historically, most of the splenectomies have resulted following the diagnosis of a hemoabdomen. Since ultrasound has become more common, we are seeing some cases with a nodule that was visualized even though this wasn't the reason for the imaging. Fine needle aspirates of the mass may provide evidence of neoplasia, but lack of findings does not rule out neoplasia. Many patients that are admitted with a hemoabdomen have had symptoms of a hemoabdomen in the past. Severe cases may result in symptoms of shock while there are other cases where an uncharacteristic lack of energy has been noted. In the latter cases, most of these patients will reabsorb the blood in to the body and return to normal after 1-2 days.

Splenic torsion is an occasional condition in which splenectomy is indicated. This is most commonly associated with gastric dilatation and volvulus, but it can be seen independently. The symptoms of a splenic torsion mimic those of a mild gastrointestinal condition initially that can progress to cardiovascular collapse and shock. Splenic enlargement may be seen on radiography, and an ultrasound should be useful for a diagnosis. Arterial and venous flow may be substantially altered. Splenectomy is necessary in conditions of splenic torsion because of venous thrombosis and splenic infarction.

Cats with splenomegaly may have a large to massive enlargement. A splenectomy may be indicated when there are clinical signs or if it will reduce the amount of tumor burden in order to improve the outcome with chemotherapy.

Diagnostics include a CBC and chemistry profile with a urinalysis, chest radiography, and ultrasonography. A cardiac ultrasound can be useful to assess potential cardiac involvement. Some patients with hemangiosarcoma have atrial involvement that should be evaluated prior to surgery. If surgery is required, a general rule of thumb is that best results are achieved when patients have a packed cell volume above 25% prior to surgery and above 20% after surgery. A blood transfusion is advised if these parameters are not met to improve survival. Further monitoring post-operatively should be performed in the first 24 hours after surgery to assure that the packed cell volume remains stable. Consideration should be given for a coagulation profile. When possible, it should be performed along with blood typing.

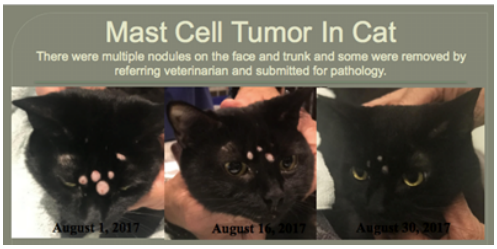

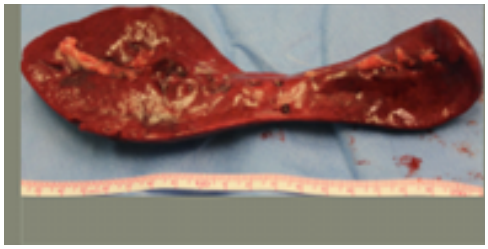

MCT cells found on cytology in spleen and liver. Splenectomy done on 8/1/17, and spleen appeared grossly normal. Cat had poor appetite and lost weight. Started on Palladia and steroids and improved substantially over 30 day period.

Surgery should be performed as soon as the patient is stable. Traumatic conditions resulting in a splenectomy may also have liver fractures and other potential soft tissue injuries, and those must also be addressed. Most surgeons don't perform partial splenectomies in spite of literature in the past. This might be possible with trauma but when neoplasia is suspected, it could easily spread into the other parts of the spleen.

A midline incision is typically performed. When the spleen is large, it should be started at the xyphoid process and continue posterior to the umbilicus. In males, the incision will likely extend on one side or the other of the prepuce. Once the abdomen is opened, fluid is aspirated and quantitated. Aspirated blood should rarely be used for an autotransfusion because of the possibility of malignant cells in the abdomen. An exception can be made for patients with hemorrhage as a result of trauma. The spleen should be exteriorized from the abdomen. This is best done using gentle pressure on both sides of the abdomen to press it to the incision line. If the incision is too short, it can be lengthened at this point before continuing. Hands can be used to assist removal of the spleen, but it is often easily torn or already torn and additional hemorrhage may result during exteriorization. Care must be taken when the spleen emerges from the abdomen. The spleen must be supported to prevent if from falling from the table. Additionally, when the vessels are under tension, hemorrhage is more likely to occur.

(Continued on next page)

(Continued from previous page)

Jorga -
Golden Retriever

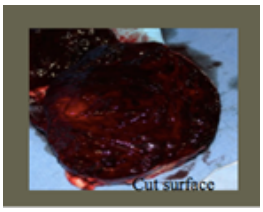

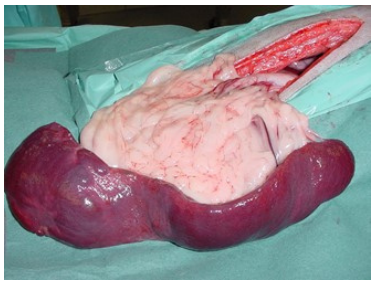

Large spleens will require support to prevent them from creating excessive tension on the vasculature and potentially falling off the table.

Typically, when performing splenectomies, the vessels are tied close to the spleen individually. The Harmonic scalpel™ uses ultrasound technology to seal and divide vessels. Some surgeons will use bipolar forceps to seal the vessels and then divide them. The LigaSure™ device uses bipolar technology and is preferred by the surgeons at VCSG. LigaSure™ vessel sealing technology has been improved with the Force Triad™ energy platform and has a patented sensing technology that uses the body's own collagen and elastin to create a permanent fusion zone. This technology can safely fuse vessels up to and including 7 mm, lymphatics and tissue bundles. This usually takes about 2-4 seconds in most surgical situations.

The use of the LigaSure Force Triad™ in surgery has been clinically shown to significantly reduce operative blood loss, perioperative blood transfusions and surgical procedural time in human surgery. Veterinary surgeons are seeing similar trends. Surgical hemorrhage and procedure time in particular are reduced. I will typically use this hand piece to perform a liver biopsy at the same time. The hemorrhage is remarkably reduced when using this technology in the liver.

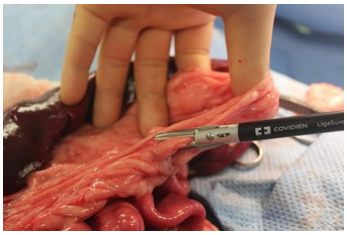

The liver is evaluated after the spleen is removed. There are times where there is liver involvement and biopsies are almost always obtained even when seemingly normal.

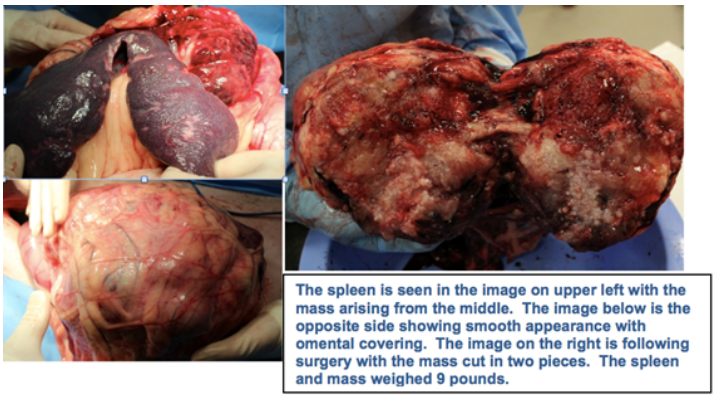

The spleen is seen in the image on upper left with the mass arising from the middle. The image below is the opposite side showing smooth appearance with omental covering. The image on the right is following surgery with the mass cut in two pieces. The spleen and mass weighed 9 pounds.

Post-operative care is provided with fluid therapy with blood as needed, blood pressure, heart rate and gum color. Because about 60% of the patients have arrhythmias, a continuous or intermittent ECG should be used at least overnight. If arrhythmias are not encountered in the first 24 hours, it is unlikely that they will be seen. We usually follow up with packed cell volume checks over the first 24 hours to assure that the levels remain normal.

The prognosis following splenectomy is good overall. If neoplastic diseases are seen, the prognosis is dependent upon the disease.